

## SLEEP MEDICINE PEARLS

## When Sleeping With Eyes Closed Is Optional

Lourdes M. DelRosso, MD, FAASM<sup>1,2</sup>; Dustin Lehnert, BS, RPSGT, RRT<sup>1</sup>; Maida Lynn Chen, MD<sup>1,2</sup><sup>1</sup>Seattle Children's Hospital, Seattle, Washington; <sup>2</sup>University of Washington, Seattle, Washington

A 7-year-old girl is referred for sleep evaluation because of parental concern of “sleeping with her eyes open.” She was referred by an ophthalmologist, who had been consulted for the patient’s complaints of dry eyes in the morning. Recommendations included an eye lubricant and a full sleep evaluation.

A pediatric sleep evaluation revealed that the patient had a routine bedtime of 9:00 PM and fell asleep on her own in her own bed and in her own room. Parents reported that during routine checks after she had fallen asleep, they noticed that the patient’s eyes appeared open despite appearing to be asleep. As parents were unsure if she was awake or asleep, the patient was given melatonin 3 mg to ensure sleep. The patient was then observed to behaviorally fall asleep, but her eyes failed to close. Once asleep, the patient’s parents reported snoring and mouth breathing, but denied witnessed apneas, restless sleep, restless legs, leg kicking, nightmares, night terrors, or sleepwalking. The patient reportedly awoke routinely at 8:00 AM appearing refreshed. Once awake, she denied daytime sleepiness. The patient otherwise was in good health with appropriate development, with no significant past medical or surgical history. Extended family history was notable for severe sleep apnea in

a grandparent and an aunt, but negative for nocturnal lagophthalmos or other ophthalmologic disorders. The patient had a normal physical examination for age, including typical symmetric facial structure, normal eye and eyelid examination, and size 1+ tonsils.

A sleep study was obtained to evaluate for obstructive sleep apnea given history of snoring. The following results were reported: total sleep time of 522 minutes, sleep latency of 8.3 minutes, sleep efficiency of 95.9%, and an arousal index of 7 events/h. The percent of time spent in each sleep stage was: N1 4.5%, N2 43.4%, N3 34.5%, and R 17.6%. The respiratory parameters showed an obstructive apnea-hypopnea index of 1 event/h without significant central apneas or hypoventilation, and a nadir oxygen saturation of 94.7%. The patient was recorded having her eyes open during electroencephalographic rapid eye movement (**Figure 1**) and non-rapid eye movement sleep (**Figure 2**); see also **Video 1** and **Video 2** in the supplemental material.

**QUESTION: What is your diagnosis?**

Figure 1—Epoch representing rapid eye movement sleep during Video 1.

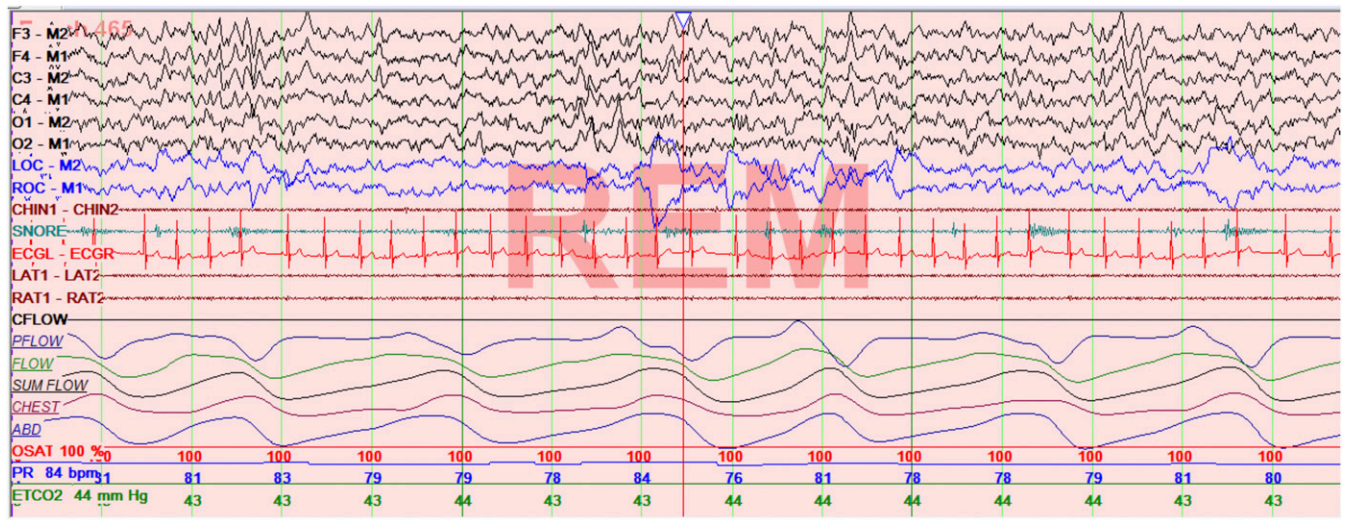
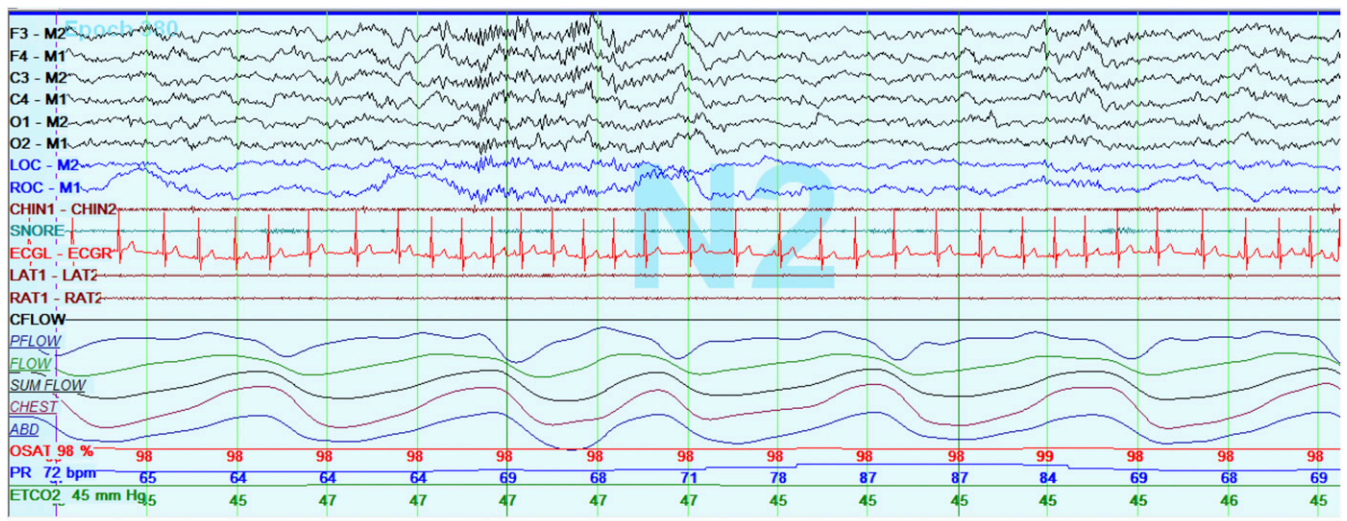


Figure 2—Epoch representing non-rapid eye movement sleep during Video 2.



**ANSWER: Nocturnal lagophthalmos**

**DISCUSSION**

Incomplete closure of the eyelids during sleep, called nocturnal lagophthalmos, has been rarely reported in the medical literature, with little known about the epidemiology or clinical characteristics of this disorder. Five percent of adults are estimated to sleep with their eyes open, making the condition relatively common.<sup>1</sup> In a cohort of 42 adults with nocturnal lagophthalmos, 57% were women and 84% had unilateral lagophthalmos. In this cohort, all participants reported foreign body sensations in their eyes, but only 17% had eye redness.<sup>2</sup> Prevalence and clinical characteristics about this disorder remain unknown in children. A single polysomnography case

report in a 5-year-old girl with nocturnal lagophthalmos showed eye movements during non-rapid eye movement sleep.<sup>3</sup> In 1967, Mueller published an observational study of children of the Amharic descent, who slept with their eyes open. However, prevalence was not reported.<sup>4</sup>

Although eyes move in all directions during sleep, it is routinely accepted that with eyelid closure, the eyes move up and out (lateral). In 1923, Sir Charles Bell postulated that during sleep, the eye rolled upward to protect the cornea. In 1936, Hall examined 234 patients during sleep and concluded that the eyes could be found in different positions.<sup>5</sup> Closure of the eyelid is necessary for tear distribution across the eye during sleep. The inability to fully close the eyelid leads to corneal exposure, dryness of the eye, keratitis, and/or corneal abrasion.<sup>6</sup>

Clinically, lagophthalmos can be seen in patients with anatomic conditions that make it functionally harder to close the eyelid completely (eg, proptosis) or anatomic deficiencies surrounding eyelid (eg, palpebral insufficiency), heavy alcohol

Downloaded from jcsm.aasm.org by 49.145.234.186 on March 22, 2022. For personal use only. No other uses without permission. Copyright 2022 American Academy of Sleep Medicine. All rights reserved.

ingestion, and use of sedative hypnotics. However, most cases are of unknown etiology.<sup>1</sup> An interesting association has been found between nocturnal lagophthalmos and urofacial syndrome, which is characterized by a paradoxical inversion of the corners of the mouth when laughing giving the impression of crying and frequent severe urinary infections. Mermerkaya et al reported nocturnal lagophthalmos in 12 of 15 children with urofacial syndrome.<sup>6</sup> In this study, nocturnal lagophthalmos was reported either by a parent or by a medical professional during a hospitalization. The patients' eye symptoms included morning redness, tearing, discomfort or foreign body sensation.<sup>6</sup> Overall, this matches generally reported presenting symptoms of nocturnal lagophthalmos, which may include waking with dry eyes, soreness, redness, foreign body sensation, or blurry vision.

Diagnostic evaluation for nocturnal lagophthalmos includes assessing the persistence of morning eye complaints throughout the day. Obtaining history of trauma, eye surgery, Bell palsy, thyroid disease, or previous cosmetic procedures should be done. Family history may reveal a first-degree relative with the same condition.<sup>4</sup> When available, slit-lamp examination is recommended to check for presence of scarring, vascularization, or punctate lesions in the lower third of the cornea.<sup>1</sup> Ophthalmologic evaluation may be needed for thorough examination, and craniofacial/otolaryngologic specialists may be consulted to evaluate for any contributing anatomic differences that prevent full eyelid closure. Treatment should first include patient/family reassurance. Next, medical treatment is aimed at preventing corneal injury and desiccation, which may involve ocular lubricants, or mechanical closure of eyelids using weights on eyelids or taping them shut.

The patient discussed in this report had a normal evaluation by ophthalmology, and a normal evaluation by our craniofacial specialists with no evidence of proptosis or craniofacial abnormalities. The family was offered gold eyelid weights or platinum chains to keep her eyelids closed during sleep, but they opted to continue ointment application to her eyes during sleep. The patient remains otherwise healthy at this time with no visual impairment.

## SLEEP MEDICINE PEARLS

1. The prevalence of nocturnal lagophthalmos is unknown in children.

2. Children with nocturnal lagophthalmos can be identified during video polysomnography.
3. Treatment options include techniques to avoid eye drying (tape closing the eyelid, or lubrication of the eye during sleep).

## CITATION

DelRosso LM, Lehnert D, Chen ML. When sleeping with eyes closed is optional. *J Clin Sleep Med*. 2019;15(10):1551–1553.

## REFERENCES

1. Latkany RL, Lock B, Speaker M. Nocturnal lagophthalmos: an overview and classification. *Ocul Surf*. 2006;4(1):44–53.
2. Lyons CJ, McNab AA. Symptomatic nocturnal lagophthalmos. *Aust N Z J Ophthalmol*. 1990;18(4):393–396.
3. Piccolo B, Pisani F. Slow eye movements in idiopathic familial nocturnal lagophthalmos. *Sleep Med*. 2014;15(10):1279–1281.
4. Mueller FO. Lagophthalmos during sleep. *Br J Ophthalmol*. 1967;51(4):246–248.
5. Hall AJ. Some observations on the acts of closing and opening the eyes. *Br J Ophthalmol*. 1936;20(5):257–295.
6. Mermerkaya M, Sürer E, Öztürk E, et al. Nocturnal lagophthalmos in children with urofacial syndrome (Ochoa): a novel sign. *Eur J Pediatr*. 2014;173(5):661–665.

## ACKNOWLEDGEMENTS

Author contributions: Dr. DelRosso and Dr. Chen have written the manuscript, Mr. Lehnert has contributed with images, editing and polysomnographic data.

## SUBMISSION & CORRESPONDENCE INFORMATION

Submitted for publication December 27, 2018

Submitted in final revised form July 16, 2019

Accepted for publication July 16, 2019

Address correspondence to: Lourdes M. DelRosso, MD, FAASM, Seattle Children's Hospital, 4800 Sand Point Way NE, Seattle, WA 98105; Email: lourdesdelrosso@me.com

## DISCLOSURE STATEMENT

Work for this study was performed at Seattle Children's Hospital. The authors report no conflicts of interest.