

CASE REPORTS

Severe Postictal Hypoxemia-Associated Seizure in a 12-Year-Old Child

Lourdes M. DelRosso, MD^{1,2}; Romy Hoque, MD³; Crystal Mitchell, RRT-SDS, RCP¹; Ngoc P. Ly, MD, MPH^{1,2}

¹UCSF Benioff Children's Hospital Oakland, Oakland, CA; ²Division of Pulmonary Medicine, Department of Pediatrics, University of California, San Francisco, CA; ³Emory Sleep Center, Atlanta, GA

A 9 year-old girl with developmental delay and seizure disorder presented for evaluation of witnessed breathing pauses during sleep that were not associated with snoring or gasping. Polysomnography showed a generalized seizure with post ictal central apnea associated with severe desaturation and a post central apnea brief seizure. This case report discusses the pathophysiology of post-ictal desaturations and breathing abnormalities during seizures and their possible association with sudden unexpected death in epilepsy. The case also demonstrates the utility of polysomnography for the diagnosis of breathing abnormalities associated with seizures.

Keywords: seizure, central apnea, octal apnea

Citation: DelRosso LM, Hoque R, Mitchell C, Ly NP. Severe postictal hypoxemia-associated seizure in a 12-year-old child. *J Clin Sleep Med* 2016;12(12):1691–1693.

REPORT OF CASE

A 9-year-old girl with developmental delay and intractable seizure disorder presented for evaluation of witnessed breathing pauses during sleep. The parents denied snoring or gasping. The breathing pauses lasted few seconds. During these episodes, the parents tried to stimulate the child; the child had no reported cyanosis and no apparent change in muscle tone. Review of systems was negative for cough, shortness of breath, gastroesophageal reflux, asthma, and allergic rhinitis. Her seizures occurred daily and were generalized tonic-clonic, with the tonic phase consisting of arm extension or flexion, head drop, or staring episodes. Her medications included divalproex 125 mg in the morning and 250 mg in the evening. On physical exam, the patient was cooperative and in no distress. Her body mass index was in the 19th percentile; she had non-syndromic facies; oropharyngeal airway was Mallampati score IV; tonsils were not visualized; neck exam showed full range of motion. The remainder of the cardiopulmonary and neurologic exams was normal.

Polysomnography showed a total sleep time of 270.5 minutes during a total recording time of 492.2 minutes. Sleep efficiency was 54% due to multiple awakenings. The EEG showed disorganized background with diffuse multifocal spike and wave activity and several brief runs of spike and wave consistent with electrographic seizure activity through the night both during NREM and wakefulness. Most events lasted only few seconds. During wakefulness there was a prolonged run of spike and wave followed by a run of central apneas with severe desaturation to a nadir of 57% (**Figure 1**). During this time, the patient appeared awake with her eyes opened but did not move. The postictal central apnea was followed by another run of spike and wave activity (**Figure 2**). There were no other scorable central apneas. The central apnea index was

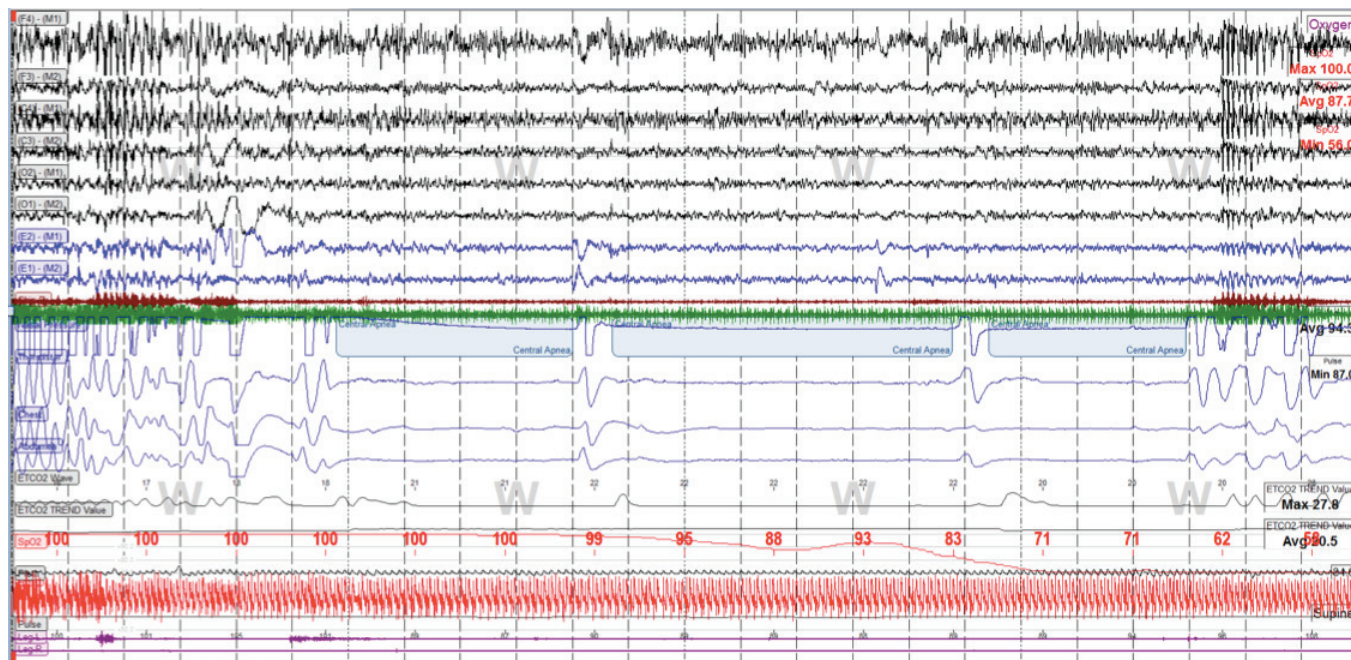
0.4 events per hour and the obstructive apnea index was 0.7 events per hour (there were 2 obstructive hypopneas). The arousal index was 25 per hour. This is high and was secondary to brief ictal activity. Snoring was not heard. The baseline oxygen saturation was 97%. The end-tidal CO₂ was below 50 Torr for the entire time. Saturations were below 90% for less than 1% of the total sleep time. Periodic leg movement index was 0 per hour.

DISCUSSION

Ictal hypoxemia is defined as a drop in oxyhemoglobin saturation below 90% during a seizure and has been seen in up to 33% of focal seizures with or without generalization. Severe ictal hypoxemia, however, is rare, has been described in less than 3% of seizures, and is defined as saturation drop below 70%. Severe hypoxemia has been reported to be associated with male gender, right temporal lobe, and seizures with contralateral spread.¹ The onset of drop in oxygen saturation is often delayed and can occur up to 60 seconds after seizure onset, with further delay in recovery to preictal oxygen saturation levels.² Compared to ictal hypoxemia, bradycardia during seizures is less common.³ Postictal hypoxemia has been associated with drop in parasympathetic tone during and after temporal lobe seizures.⁴ The hypoxemia mechanism remains unclear, but there are a couple of postulated mechanisms.

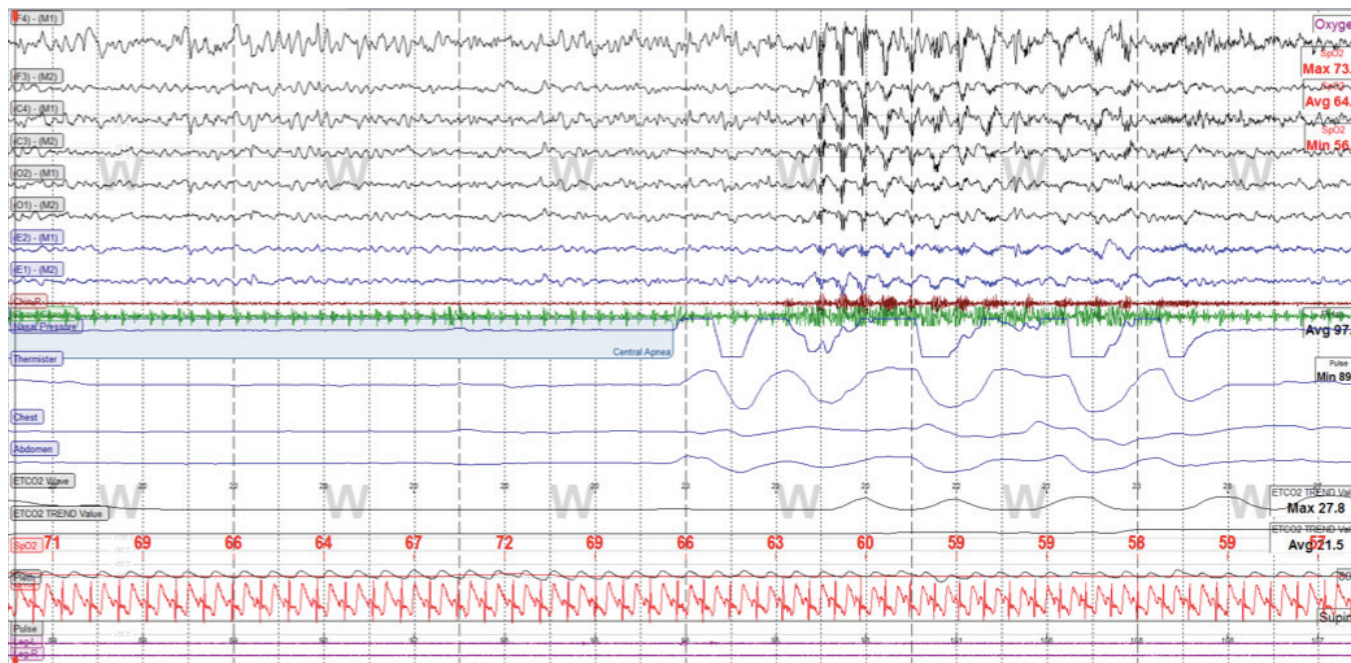
Ictal hypoxemia is often accompanied by respiratory changes. One mechanism postulates that cerebral hypoxemia suppresses the brainstem respiratory centers.⁵ The pacemaker of breathing is located in the Pre-Botzinger (PB) complex in the medulla. Pre-motor neurons project from the PB complex to spinal and respiratory motor neurons. There

Figure 1—Two minute epoch showing seizure with post ictal central apneas, desaturation, and second seizure.



Electroencephalogram leads (F4-M1, F3-M2, C3-M2, C4-M1, O1-M2, O2-M1); electromyogram leads (chin, LEGL, LEGR), Ocular leads (E1-M2, E2-M1), respiratory sensors (nasal pressure) EKG leads, SpO₂ (oxyhemoglobin saturation), PWF (pulse wave form).

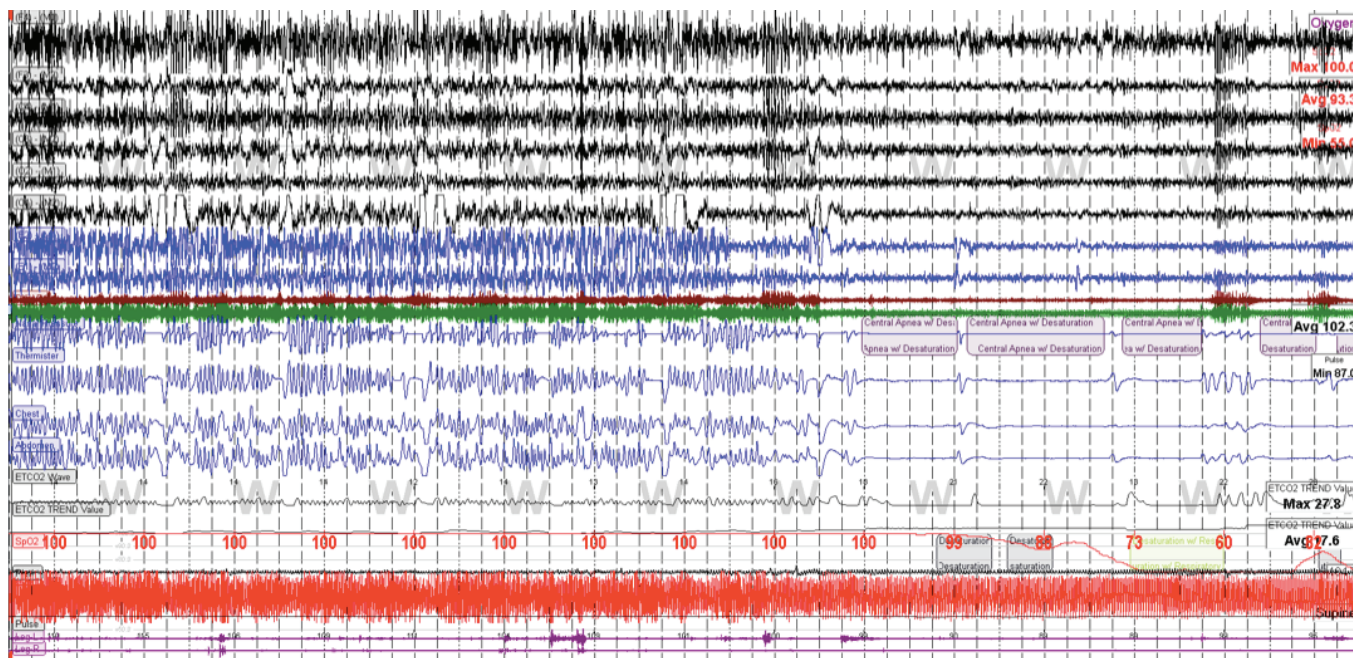
Figure 2—Thirty second epoch showing central apnea desaturation and seizure.



Electroencephalogram leads (F4-M1, F3-M2, C3-M2, C4-M1, O1-M2, O2-M1); electromyogram leads (chin, LEGL, LEGR), Ocular leads (E1-M2, E2-M1), respiratory sensors (nasal pressure) EKG leads, SpO₂ (oxyhemoglobin saturation), PWF (pulse wave form).

are three types of neurons in the PB involved in breathing: autonomous spiking neurons, nonspecific cation current-dependent pacemaker neurons, and persistent sodium current pacemaker neurons (INaP). During hypoxemia, the two former neuron groups are silenced and the breathing pacemaker

becomes dependent on INaP, which produces gasping. Central apneas are the most common respiratory abnormality during seizures, occurring both in adults and children with an average length of 49 seconds.⁶ A second mechanism postulates that the washout of carbon dioxide during the initial

Figure 3—Five minute recording shows prolonged run of epileptic discharges prior to run of central apneas.

Brief non-scorable central apneas between ictal discharges.

tachypnea seen at seizure onset produces ictal central apnea.⁷ Young children with symptomatic generalized, longer duration, temporal lobe seizures have been found to be at higher risk for central apnea with desaturation.⁷ Seizures with post-ictal generalized EEG suppression are likely to have longer and more profound desaturations.⁶ Respiratory abnormalities during seizures in combination with cardiac abnormalities are thought to cause sudden unexpected death in epilepsy (SUDEP).

The consequences of hypoxemia in general include pulmonary hypertension, cognitive and behavioral deficits, and failure to thrive, among others. There are limited data and no current guidelines on the administration of oxygen during seizures. The British Thoracic Society states that intermittent oxygen therapy at home is not recommended for seizures.⁸

Our patient had a history of intractable epilepsy and multiple epileptic discharges during wakefulness and during sleep. A run of central apneas followed a prolonged run of seizure activity (**Figure 1** and **Figure 3**) followed by a brief seizure after the central apneas (**Figure 2**). It is unclear if this second event was due to hypoxemia. The patient continues care with neurology for optimization of seizure control.

ABBREVIATIONS

BMI, body mass index
 EEG, electroencephalogram
 OSA, obstructive sleep apnea
 PB, pre-botzinger complex
 SUDEP, sudden unexpected death in epilepsy

REFERENCES

- Maglajlija V, Walker MC, Kovac S. Severe ictal hypoxemia following focal, subclinical temporal electrographic scalp seizure activity. *Epilepsy Behav* 2012;24:143–5.
- Rugg-Gunn F, Duncan J, Hjalgrim H, Seyal M, Bateman L. From unwitnessed fatality to witnessed rescue: nonpharmacologic interventions in sudden unexpected death in epilepsy. *Epilepsia* 2016;57 Suppl 1:26–34.
- Moseley BD, Nickels K, Britton J, Wirrell E. How common is ictal hypoxemia and bradycardia in children with partial complex and generalized convulsive seizures? *Epilepsia* 2010;5:1219–24.
- Szurhaj W, Troussiere AC, Logier R, et al. Ictal changes in parasympathetic tone: prediction of postictal oxygen desaturation. *Neurology* 2015;85:1233–9.
- Moseley BD, Britton JW, Nelson C, Lee RW, So E. Periictal cerebral tissue hypoxemia: a potential marker of SUDEP risk. *Epilepsia* 2012;53:e208–11.
- Kennedy JD, Seyal M. Respiratory pathophysiology with seizures and implications for sudden unexpected death in epilepsy. *J Clin Neurophysiol* 2015;32:10–3.
- Singh K, Katz ES, Zarowski M, et al. Cardiopulmonary complications during pediatric seizures: a prelude to understanding SUDEP. *Epilepsia* 2013;54:1083–91.
- Balfour-Lynn IM, Field DJ, Gringras P, et al. BTS guidelines for home oxygen in children. *Thorax* 2009;64 Suppl 2:ii1–26.

SUBMISSION & CORRESPONDENCE INFORMATION

Submitted for publication May, 2016

Submitted in final revised form June, 2016

Accepted for publication July, 2016

Address correspondence to: Lourdes M. DelRosso, MD, University of California, San Francisco, CA; Email: Lourdes.delrosso@ucsf.edu

DISCLOSURE STATEMENT

This was not an industry supported study. Dr. Ngoc Ly has the following conflict of interest to report not related to this publication: Intellectual property rights at Knox Diagnostics. The other authors have indicated no financial conflicts of interest.