pii: jc-00469-15 http://dx.doi.org/10.5664/jcsm.5902

JCSM
Journal of Clinical Sleep Medicine

CASE REPORTS

Can We Assess Pulsus Paradoxus through Polysomnography in a Patient with Chronic Obstructive Pulmonary Disease and Sleep-Disordered Breathing?

Cesar Liendo, MD[1,2]; Ashtaad Dalal, MD[1,2]; Esther Hinds, MD[1,2]; Samreena Sara, MD[1,2]; Oleg Chernyshev, MD[1,2]; Swathi Nutakki, MD[1,2]; Jorge Rey de Castro, MD[3]; Andrew Chesson, MD[1]

[1]Louisiana State University Health Science Center Sleep Disorders Center, Shreveport, LA; [2]Overton Brooks VA Medical Center Sleep Disorders Center, Shreveport, LA; [3]Clinica Anglo Americana, Lima Peru School of Medicine Professor, Universidad Peruana Cayetano Heredia, Lima, Peru

Pulsus paradoxus (PP) is a decrease in systolic blood pressure greater than 10 mm Hg during inspiration that occurs in various medical conditions. Using polysomnography pulse oximetry signal, photoplethysmography variations of the amplitude of the pulse pressure within the respiratory cycle were observed. There is a proportional relationship between the changes of inspiratory waveform values and the generated PP. A 59-year-old male underwent polysomnography that showed sleep hypoxemia, obstructive sleep-disordered breathing (apnea hypopnea index [AHI] = 5.1and respiratory disturbance index [RDI] = 87.9), with variations of pulse pressure induced primarily by inspiration. The highest variations in the pulse wave were observed in NREM sleep during obstructive respiratory events and in biocalibration during nasal breathing. The lowest variations occurred after the correction of inspiratory obstructive events and during biocalibration when asked to hold his breath.

Keywords: chronic obstructive pulmonary disease, pulsus paradoxus, sleep-disordered breathing, inspiratory flow limitation event, photoplethysmography
Citation: Liendo C, Dalal A, Hinds E, Sara S, Chernyshev O, Nutakki S, de Castro JR, Chesson A. Can we assess pulsus paradoxus through polysomnography in a patient with chronic obstructive pulmonary disease and sleep-disordered breathing? *J Clin Sleep Med* 2016;12(6):917–919.

INTRODUCTION

In various cardiopulmonary medical conditions the reduction in systolic blood pressure greater than 10 mm Hg during inspiration is known as pulsus paradoxus (PP). During polysomnography, pulse pressure (the difference between the systolic and diastolic capillary pressures) can potentially be monitored by pulse oximeter photoplethysmography, and this can be used to evaluate the patient's pulse pressure variability induced by the respiratory cycle.[1] PP is measured by calculating (maximum amplitude minus minimum amplitude/maximum amplitude plus minimum amplitude) × 0.5. This allows one to estimate the changes in PP when upper airway obstruction occurs during sleep.[2]

REPORT OF CASE

A 59-year-old male with hypertension, type 2 diabetes mellitus, coronary artery disease, hypothyroidism, chronic obstructive pulmonary disease (COPD; home oxygen dependent), tobacco use (> 80 pack years), and a body mass index of 41.9, who had a positive nuclear stress test, underwent left heart catheterization (LHC). LHC showed triple vessel disease, and subsequently coronary artery bypass grafting (CABG) was planned. A split-night sleep polysomnography was completed prior to his CABG, prompted by patient complaints of snoring and witnessed apneas. During the diagnostic portion of the polysomnography, AHI was 5.1 and RDI was 87.9. His oxygen saturation nadir was 87%. Analysis of the patient's polysomnography showed that when the patient had an inspiratory flow limited respiratory event (IFLE), the pulse arterial wave (PAW) signal was significantly reduced on inspiration, and subsequently improved when the respiratory event ended, suggestive of PP (**Figure 1**). Through manual calculations, the PP and plethysmograph variability index (PVI = [max amplitude minus min amplitude/max amplitude] × 100) were obtained from the polysomnography, showing that during awake breathing the PVI was 43.47 and PP: 13.8%, and during episodes of obstructive sleep-disordered breathing, the PVI was 76.47 and PP: 30.9%. Following CABG, his oxygen saturation remained below 90% (likely exacerbated by preexisting COPD, and the patient was discharged home on 2 liters of oxygen, with a plan to start the patient on continuous positive airway pressure therapy. Postoperative pulmonary function tests showed moderate airflow obstruction.

DISCUSSION

In anesthesiology, noninvasive continuous pulse wave monitoring of the pulse oximetry signal has been used to detect airflow obstruction and guide fluid resuscitation.[1] In sleep medicine, pulse oximetry has been used to assess hemoglobin saturation. Recently, the PAW analysis obtained by photoplethysmography has been used to evaluate the autonomic response induced by an arousal.[3]

Analysis of the patient's polysomnography shows that when the patient had an IFLE, the PAW signal was significantly reduced on inspiration, and subsequently improved when the respiratory event ended. This phenomenon meets

Downloaded from jcsm.aasm.org by 45.89.173.196 on March 24, 2022. For personal use only. No other uses without permission.
Copyright 2022 American Academy of Sleep Medicine. All rights reserved.

Figure 1—1 minute epoch from polysomnography.

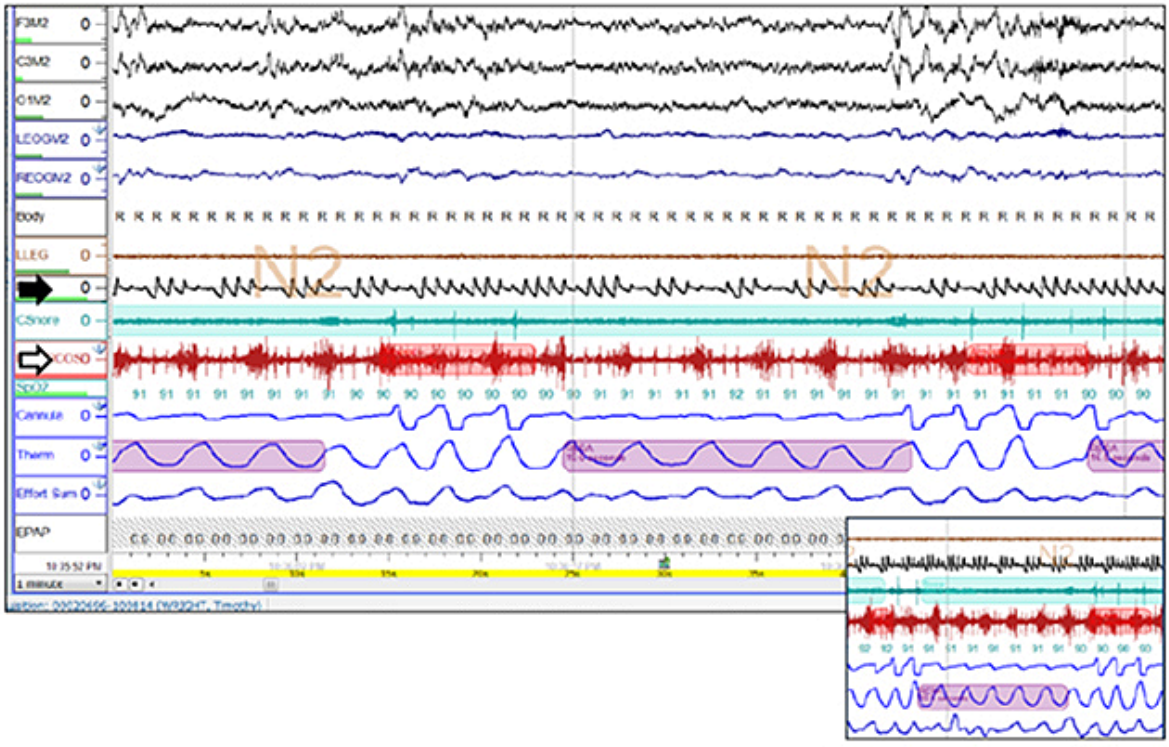

Black arrow is changes in photoplethysmography. White arrow is intercostal lead; shows inspiratory effort. Post-inspiratory attenuation of the photoplethysmography signal occurs during flow limitations, improves during expiration, resolves during recovery breathing. IFLE tagged in purple. Inset: 2 min epoch with phasic pattern correlating with respiratory cycle.

the definition of PP and represents a transient decrement of left ventricular stroke volume.[4]

Many factors can decrease the amplitude of the PAW signal during an IFLE. When this occurs, there is a leftward shift of the interventricular septum.[5] The negative intrapleural pressure generated increases pulmonary blood volume, and sequesters fluid from the intravascular compartment. Furthermore, inspiratory flow limitation of the upper airway prolongs inspiratory time and decreases expiratory time, producing auto-positive end expiratory pressure,[2] and compromises left ventricular function. This is particularly deleterious in patients with combined sleep-disordered breathing and COPD, in whom the expiratory time is reduced as much as 40% when both conditions coexist.[6]

We do not believe this constitutes a cardiopulmonary artifact since the patient remained in normal sinus rhythm, and the detected PP variability normalizes when the upper airway obstruction is relieved, and when breathing normally. In closing, we present a patient with oxygen dependent COPD who has significant attenuation of the PP, induced by IFLE. To our knowledge, this observation has not been previously described in polysomnographic literature.

ABBREVIATIONS

AHI, apnea-hypopnea index
CABG, coronary artery bypass grafting
COPD, chronic obstructive pulmonary disease
LHC, left heart catheterization
PP, pulsus paradoxus
PVI, plethysmograph variability index

REFERENCES

1. Clark JA, Lieh-Lai M, Thomas R, Raghavan K, Sarnaik AP. Comparison of traditional and plethysmographic methods for measuring pulsus paradoxus. Arch Pediatr Adolesc Med J 2004;1:48–51.
2. Shiomi T, Guilleminault C, Stoohs R, Schnittger I. Leftward shift of the interventricular septum and pulsus paradoxus in obstructive sleep apnea syndrome. Chest 1991;4:894–902.
3. Perel A. Excessive variations in the plethysmographic waveform during spontaneous ventilation: an important sign of upper airway obstruction. Anesth Analg J 2014;6:1288–92.
4. Hartert TV, Wheeler AP, Sheller JR. Use of pulse oximetry to recognize severity of airflow obstruction in obstructive airway disease: correlation with pulsus paradoxus. Chest 1999;2:475–81.
5. Viola AR, Puy RJ, Goldman E. Mechanisms of pulsus paradoxus in airway obstruction. J Appl Physiol 1990;5:1927–31.
6. Biselli, P, Grossman PR, Kirkness JP, et al. The effect of increased lung volume in chronic obstructive pulmonary disease on upper airway obstruction during sleep. J Appl Physiol 2015;3:266–71.

Downloaded from jcsm.aasm.org by 45.89.173.196 on March 24, 2022. For personal use only. No other uses without permission.
Copyright 2022 American Academy of Sleep Medicine. All rights reserved.

SUBMISSION & CORRESPONDENCE INFORMATION

Submitted for publication November, 2015
Submitted in final revised form December, 2015
Accepted for publication January, 2016
Address correspondence to: Ashtaad Dalal, MD, Department of Family Medicine, 1501 Kings Highway, Shreveport, LA 71130-3932; Tel: (845) 661-5785; Fax: (318) 675-7555; Email: Ashtaad@gmail.com

DISCLOSURE STATEMENT

This was not an industry supported study. The authors have indicated no financial conflicts of interest. The work was performed at Louisiana State University Health Science Center Sleep Disorders Center, Shreveport, LA; Overton Brooks VA Medical Center Sleep Disorders Center, Shreveport, LA

Downloaded from jcsm.aasm.org by 45.89.173.196 on March 24, 2022. For personal use only. No other uses without permission.
Copyright 2022 American Academy of Sleep Medicine. All rights reserved.